

Clinical Management of the Herbst Occlusal Hinge Appliance

ARTURO VELA-HERNANDEZ, MD, DDS, PHD
FELICIDAD LASAGABASTER-LATORRE, MD, DDS
JOSÉ M. PONCE DE LEÓN, DDS
IVÁN RICO-LILLO

Variations of the Herbst* appliance^{1,2} fall into two basic categories: fixed and removable. Studies have found similar clinical results, although the fixed appliances seem to produce a slightly greater mandibular growth effect and

*Registered trademark of Dentaurem, Inc., 10 Pheasant Run, Newtown, PA 18940.

less lower incisor proclination.^{3,4} The major advantage of the removable appliances is the reduced likelihood of loosening or breakage,⁵ while their main disadvantage is the need for patient cooperation.

This article describes a new version of the removable acrylic-splint Herbst appliance, called

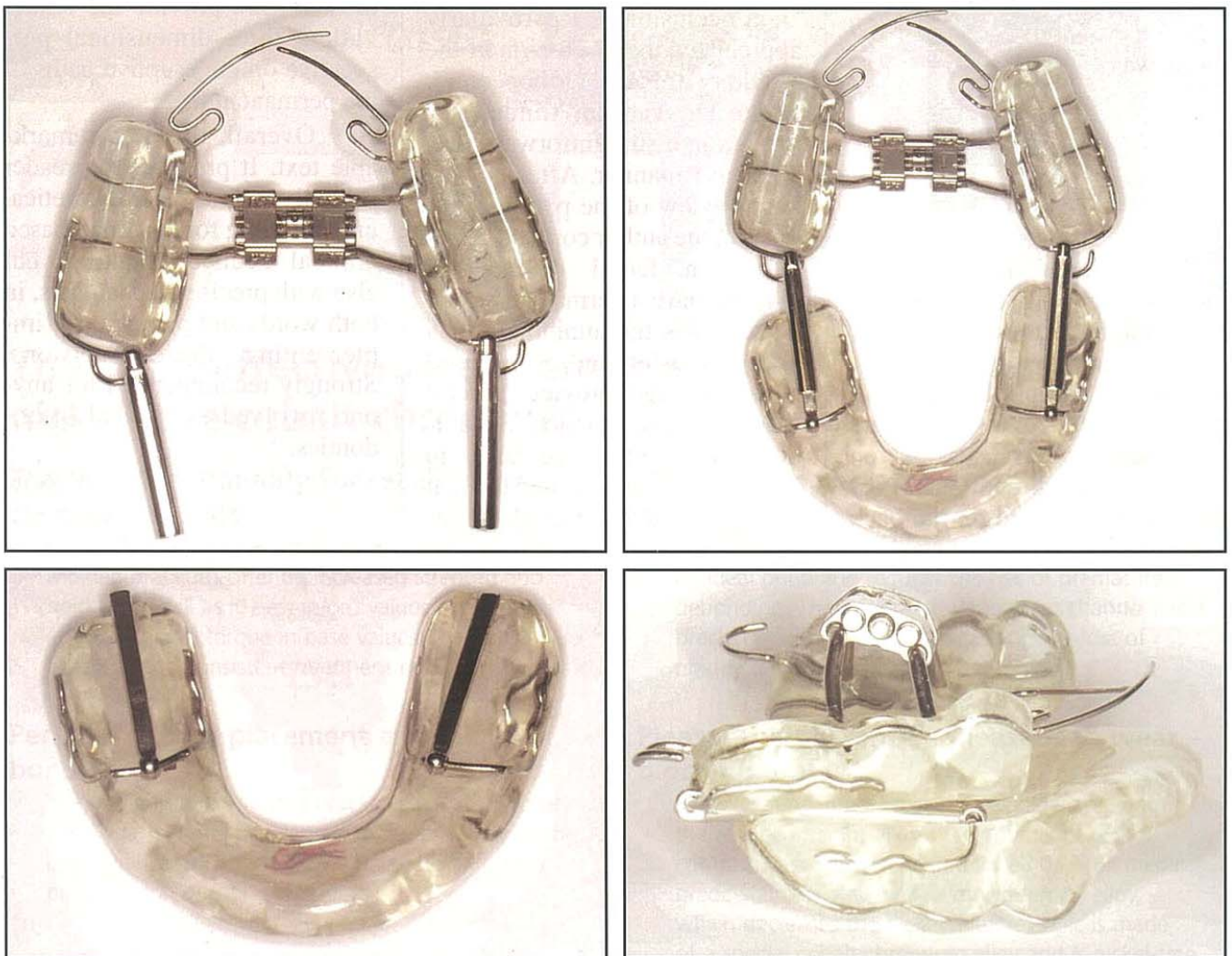

Fig. 1 Herbst Occlusal Hinge (HOH) appliance. Upper splint is combined with optional expansion screw and lingual arms.

Drs. Vela-Hernandez and Lasagabaster-Latorre are in the private practice of orthodontics at Calle Independencia, 14, 1º, 01005 Vitoria, Spain; e-mail: vela@informed.es. Dr. Ponce de León is in the private practice of orthodontics and Mr. Rico-Lillo is a laboratory technician in Alicante, Spain.



Dr. Vela-Hernandez

Dr. Lasagabaster-Latorre

Dr. Ponce de León

Mr. Rico-Lillo

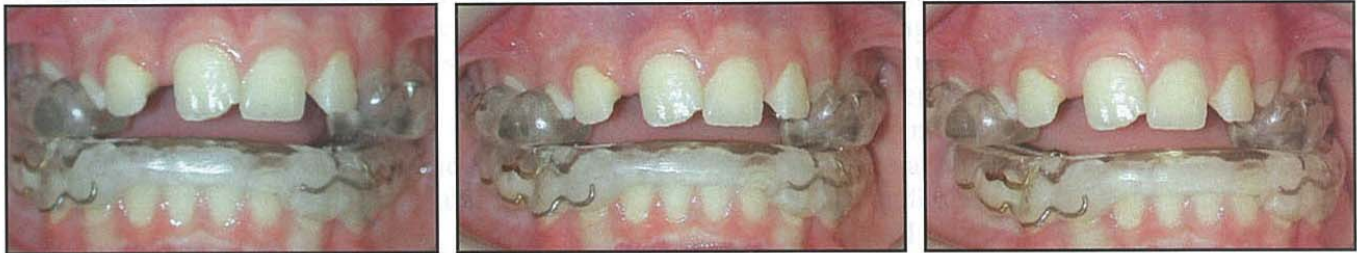

Fig. 2 Physiologic lateral movements allowed by HOH.

the Herbst Occlusal Hinge (HOH). Introduced in 2002,⁶ it is sturdy, efficient, and simple to use (Fig. 1).

Appliance Design and Fabrication

The unique feature of the HOH is that the hinge is not made with a screw and nut, but rather with a transverse pin that is fastened to the corresponding splint without protruding from it. Thus, the pin and hinge are hidden from view, improving the esthetic appearance of the appliance. This simple design also optimizes mandibular movement by emphasizing the lateral component (Fig. 2), and it allows the maxilla to be expanded by more than 15mm. Most important, with the rod moved to the occlusal area, the load is applied to a hinge with two supports. This makes the appliance virtually unbreakable; in fact, our fracture rate has dropped from about 20% to less than 1%.

Laboratory instructions for fabrication of the HOH appliance should call for at least 3mm of interocclusal space for the hinges between the opposing molars. This is especially critical in cases of open bite or inadequate overbite. It is also important that the lower splint cover the incisors to provide adequate mechanical retention.

As with other functional appliances, the degree of activation of the construction bite may vary. Because no definitive results have been reported for the progressive activation concept,^{7,8}

our usual practice is to make a single mandibular advancement, with the construction bite taken at no more than 70% of the total protrusive distance.⁹ If mandibular protrusion needs to be increased during treatment, this can easily be done by soldering metal rings to the telescoping arms (Fig. 3).

Following the advice of Pancherz,^{2,10,11} we prescribe eight months of continuous wear of the HOH, with the appliance removed only for meals and oral hygiene. In uncooperative patients and in young adults with little or no growth potential, the HOH should be fixed. We recommend cementing only the upper splint, because it will be

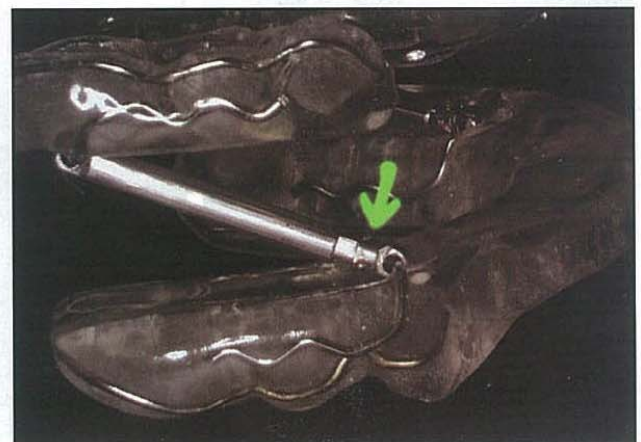


Fig. 3 When necessary, mandibular advancement can be increased progressively by soldering metal rings to telescoping arms.

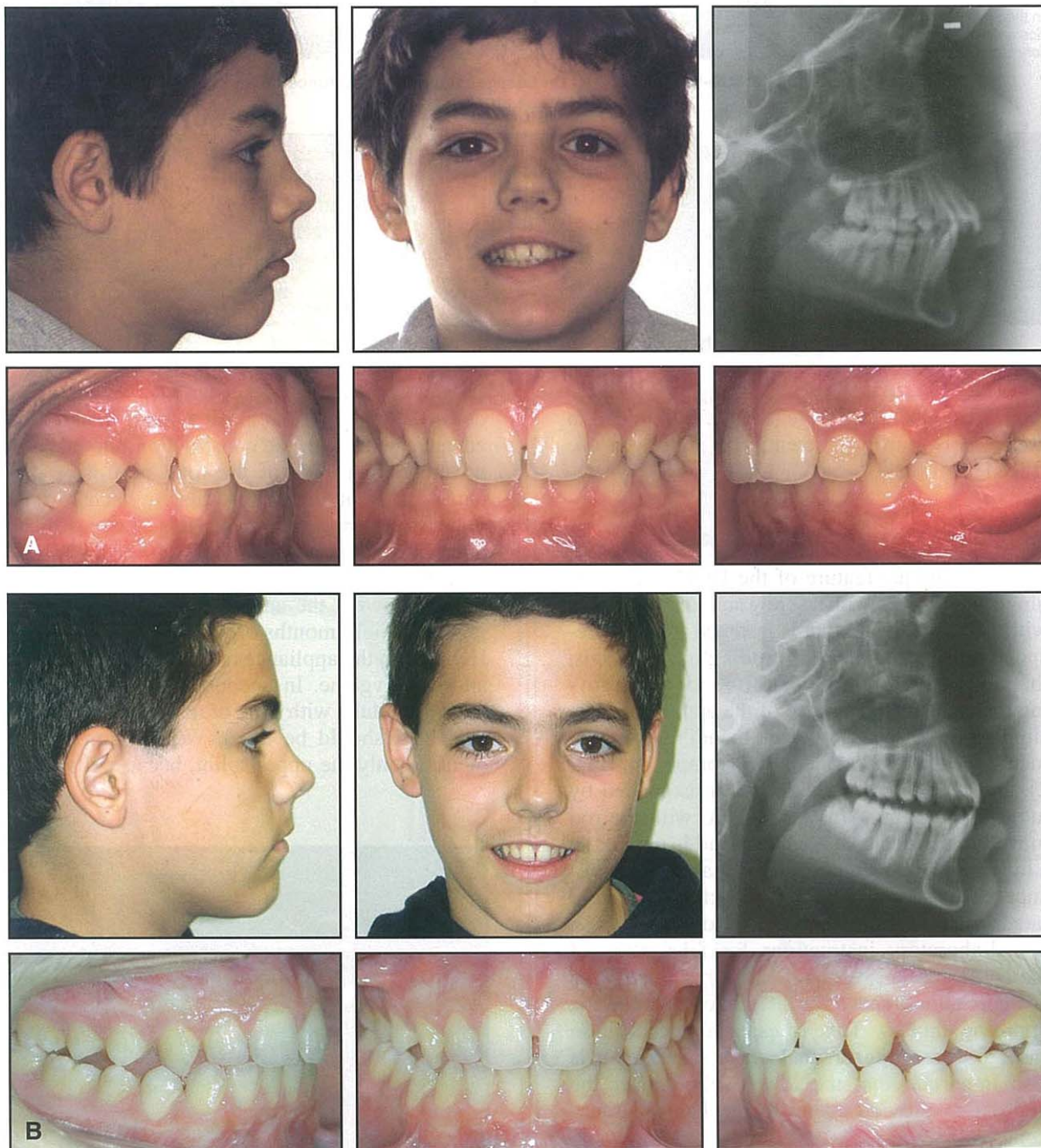


Fig. 4 A. Class II patient at end of second stage of mixed dentition. Extreme nasolabial angle required maximum mandibular advancement with minimum upper retrusion. B. After eight months of wearing removable HOH appliance, occlusion is consolidated in super-Class I relationship (continued on next page).

uncomfortable for the patient to wear an incomplete appliance, with the telescoping arms hanging freely, when the lower splint is not attached. The fixed HOH produces a full-time mandibular advancement, thus avoiding occlusal instability and the possibility of a double bite.

Indications

In general, the results achieved with the Herbst appliance will be most stable when it is worn in the permanent dentition, during or just after the peak of the pubertal growth period.¹²

Our clinical experience with the HOH appliance has led us to limit its use to the following types of patients.

1. The ideal case is a growing skeletal Class II patient in the permanent dentition or at the end of the second stage of the mixed dentition. In such a case, we can usually place fixed appliances immediately after the eight months of HOH wear to provide firm interdigitation and stability throughout the skeletal correction, and to allow the maxilla and mandible to complete their growth in a proper Class I relationship (Fig. 4).

It is not generally advisable to use a Herbst

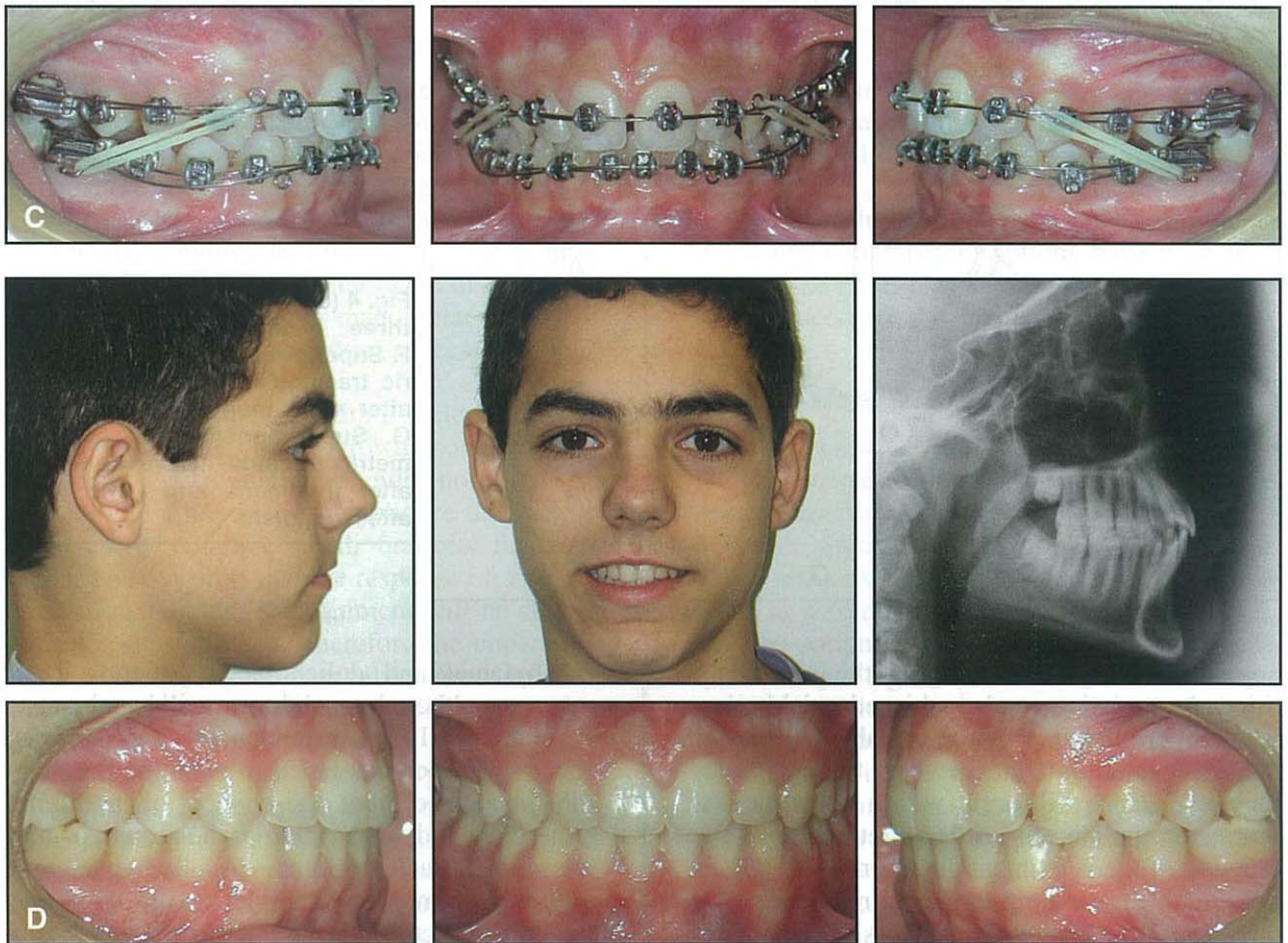


Fig. 4 (cont.) C. Placement of fixed appliances. D. After 11 months of treatment with fixed appliances (continued on next page).

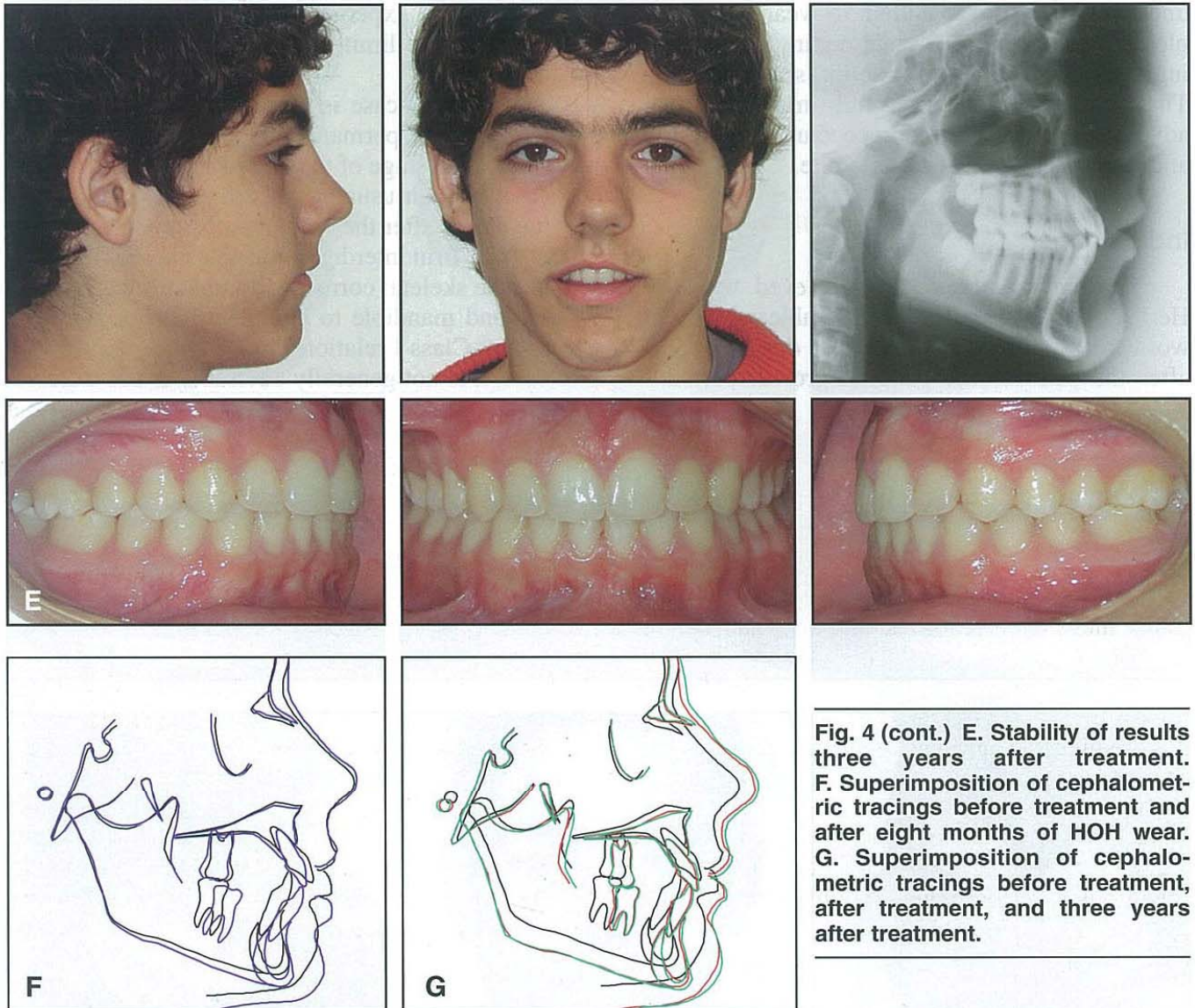


Fig. 4 (cont.) E. Stability of results three years after treatment. F. Superimposition of cephalometric tracings before treatment and after eight months of HOH wear. G. Superimposition of cephalometric tracings before treatment, after treatment, and three years after treatment.

appliance during the first stage of the mixed dentition. A correction can be achieved quickly during this period, but it will be unstable because of the weak interdigitation between the deciduous molars. Relapse will occur within a few months unless the appliance is used as a retainer until the eruption of the permanent dentition. The HOH is not suitable as a long-term retainer because it does not allow a smooth, progressive adaptation of the posterior regions.

On the other hand, and contrary to the commonly held opinion, the HOH can be used in both

brachyfacial and dolichofacial patients. Their response, although much lower, will be adequate. 2. In a Class II case where another type of functional appliance has failed to maintain the mandibular advancement, the chances of modifying either the condylar position or the growth pattern are limited. Such a patient is usually hyperactive, with a hypermobile mandible. The HOH is particularly effective because it maximizes lateral movements and, with its sturdiness of construction and ability to be cemented in place, firmly maintains the forward position of the mandible.

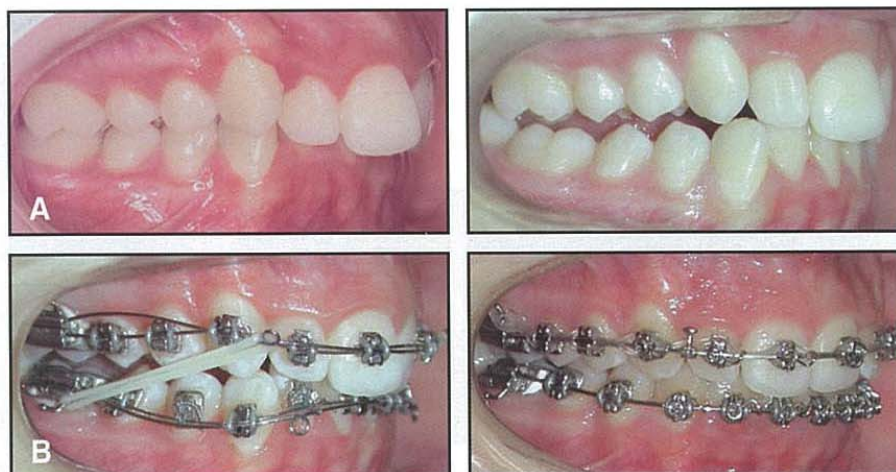


Fig. 5 A. Usual mild posterior disclusion after HOH stage of treatment. B. Disclusion resolved simply by leveling arches during initial stages of fixed appliance treatment.

3. A severe skeletal Class II patient in the first stage of the mixed dentition should be treated with a removable functional appliance, which is much more manageable at that age than later.¹² Our first choice is the HOH, especially in a patient whose labiolingual functional component is minor. With other devices, this kind of case usually requires progressive mandibular advancement or even the fabrication of successive appliances.

4. A young adult patient with a skeletal Class II malocclusion, little or no growth potential, and mandibular retrognathia should normally be treated with a fixed Herbst appliance that can be more easily combined with brackets than the HOH. The reason is that the response of a young adult to mandibular advancement will be slower and more unstable, and therefore the upper part of the HOH must be cemented to ensure its continuous use and avoid the establishment of a mandibular hypermobility habit.

Nevertheless, there are two types of young adult patients in whom the HOH may be indicated. In a case where the treatment goal is to avoid extractions or surgery, since the majority of the change produced by the HOH at this age is dentoalveolar, it can be used to assess the patient's response to mandibular advancement in a reasonably short time. In addition, in a TMD patient with asymptomatic condylar clicking due to ante-

rior displacement of the disc upon opening, the HOH can act as a stabilizing splint while advancing the mandible, before fixed appliances are used.

5. In some adult patients with snoring problems, when other therapeutic options have been ineffective, the HOH is sturdy enough to be used for an extended period of time.

Clinical Management

The basic objectives when using the HOH are to generate enough overjet to support the required mandibular advancement, and to establish posterior contacts in the shortest possible time. There are a number of more specific considerations, however, that depend on the type of case.

In patients with limited overbite and adequate overjet, eight months of continuous wear is usually sufficient. A slight posterior disclusion is typically produced as a response to mandibular advancement in the presence of a curve of Spee. With other functional devices, the disclusion is corrected over time by a natural grinding down of the appliance and the resulting passive eruption of the posterior teeth. With the HOH, the disclusion is corrected later with fixed appliances while leveling the curve of Spee, usually by extrusion of the posterior teeth (Fig. 5).

In some deep overbite cases, a severe poste-

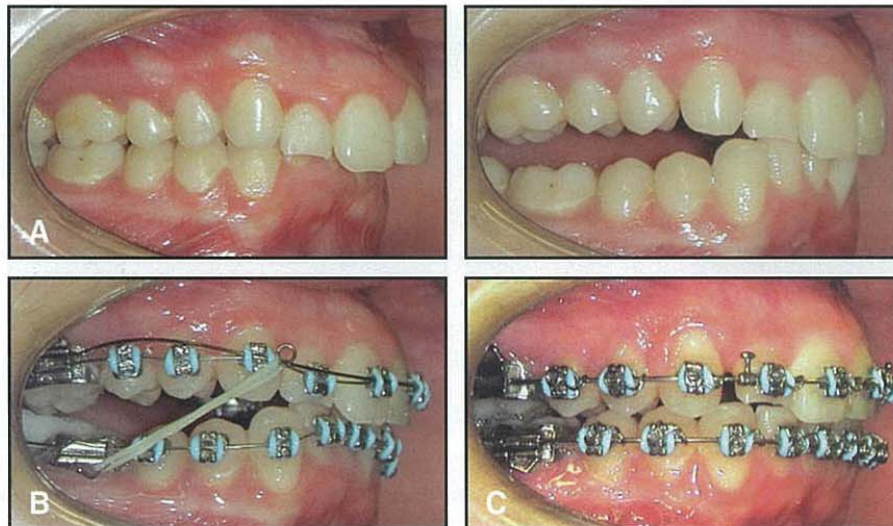


Fig. 6 A. Extreme posterior disclusion after HOH stage of treatment. B. Posterior build-ups used during leveling stage in mesofacial and dolichofacial patterns. C. Build-ups eliminated after curve of Spee is corrected, providing favorable counterclockwise mandibular rotation.

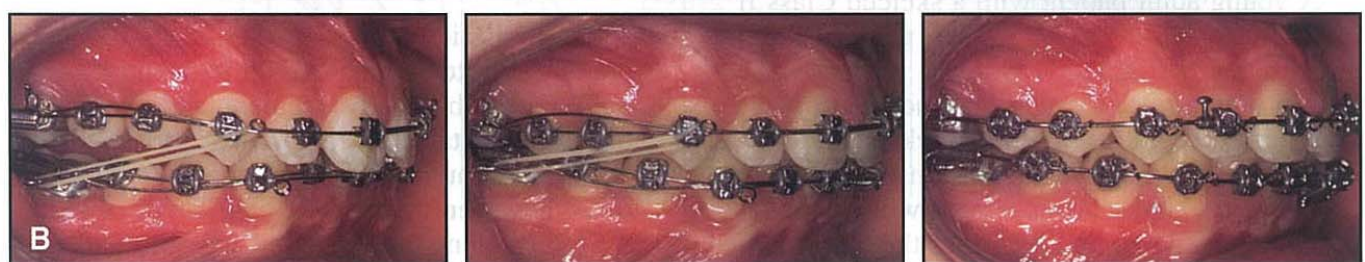
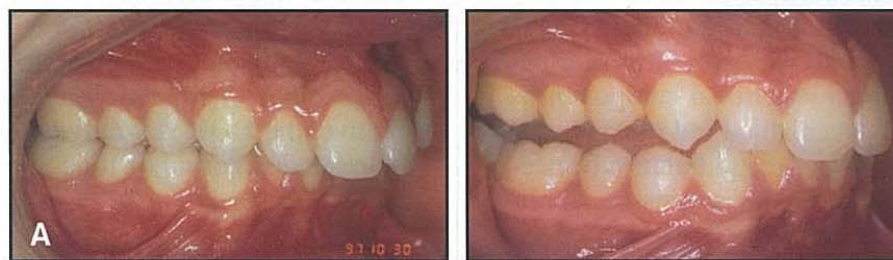

Fig. 7 A. Brachyfacial patient with extreme posterior disclusion after HOH stage of treatment. B. Bite Turbos and extrusive mechanics with Class II elastics used to produce rapid molar extrusion and provide posterior contact in shortest possible time.

rior disclusion can be produced when the anterior contact between the incisors acts as a bite-plane, causing a gradual mandibular retrusion in search of occlusal contacts, especially during mastication. It is imperative to correct this disclusion to avoid a relapse of the Class II relationship during the initial stages of fixed appliances.

In mesofacial and dolichofacial cases, after removal of the HOH, we create posterior build-ups to maintain the posterior occlusal contact and its associated proprioceptive guidance, which avoids mandibular retrusion. Once the curve of Spee is leveled, the build-ups are removed, allowing a minor, favorable counterclockwise

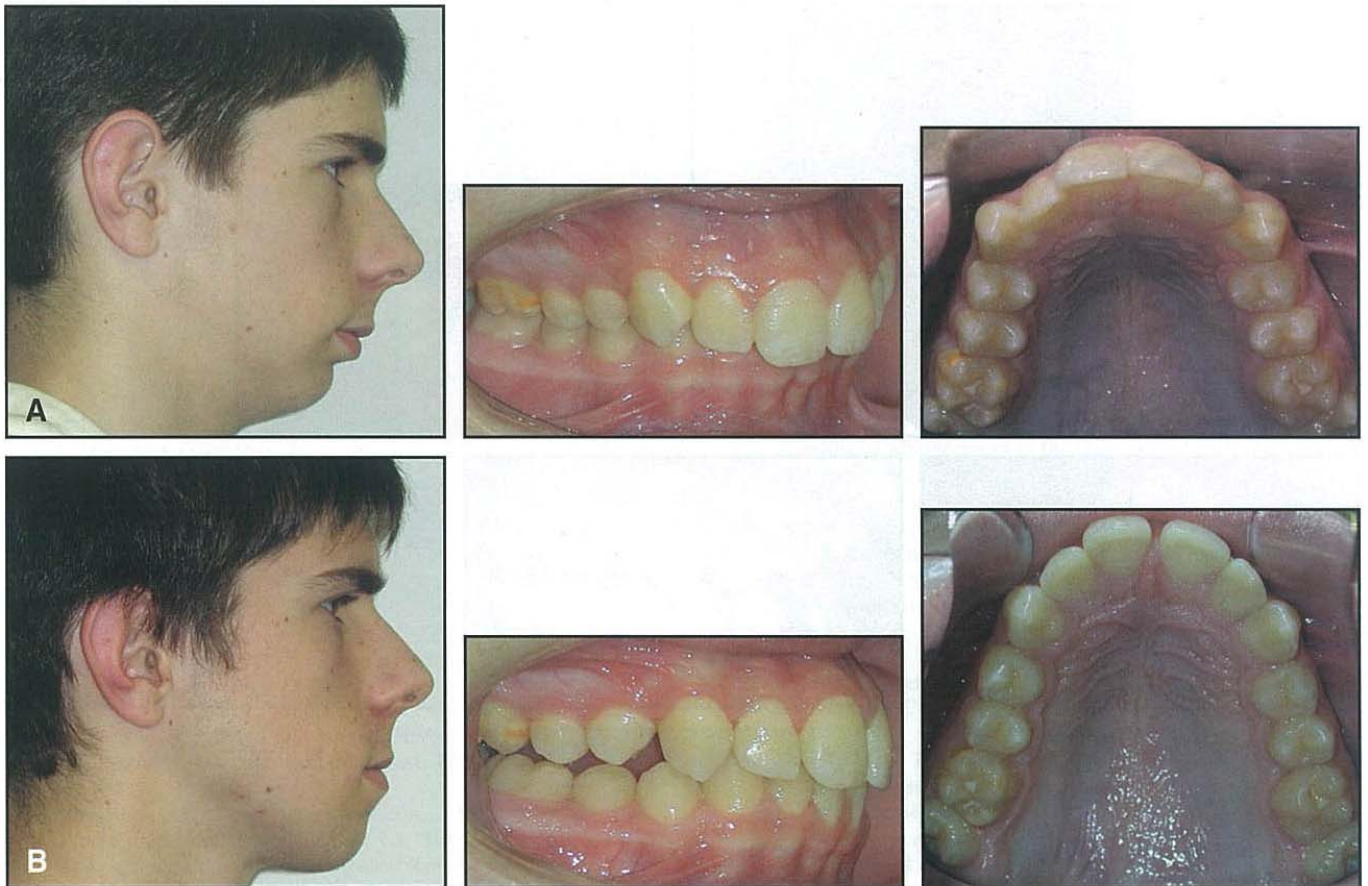


Fig. 8 A. Patient with inadequate overjet and constricted maxilla before treatment. **B.** Incisor protrusion during maxillary expansion allows sufficient mandibular advancement with HOH.

rotation of the mandible (Fig. 6). In severely brachyfacial cases, we either allow overeruption of the second lower molars during the HOH phase or, more frequently, we bond Bite Turbos** (anterior occlusal stops) to the lingual surfaces of the upper incisors to open the bite when the fixed appliances are placed. At the same time, Class II elastics are used to provide continuous extrusive forces that will level the disclusion in the shortest possible time (Fig. 7).

An inadequate overjet, due either to retroclination of the upper incisors or to anterior crowding, will obstruct the mandibular advancement and may even create an anterior crossbite. If there is a significant associated constriction of the upper arch, we can take advantage of this by protruding the incisors with upper lingual arms

during maxillary expansion (Fig. 1). These will create adequate overjet while the mandible is advanced (Fig. 8).

If the anterior crowding or maxillary constriction is too severe, if the constriction is too mild to be expanded, or if the overbite is due to overeruption of the anterior teeth (producing the classic gummy smile), it is advisable to use fixed appliances before placing the HOH. A bonded 2 × 4 appliance can correct the upper arch enough for the required mandibular advancement (Fig. 9). Rarely, a fixed HOH can be combined with upper fixed appliances during the entire eight months of wear, simply by adding tubes to the buccal areas of the functional appliance (Fig. 10).

**Ormco/"A" Company, 1717 W. Collins Ave., Orange, CA 92867.

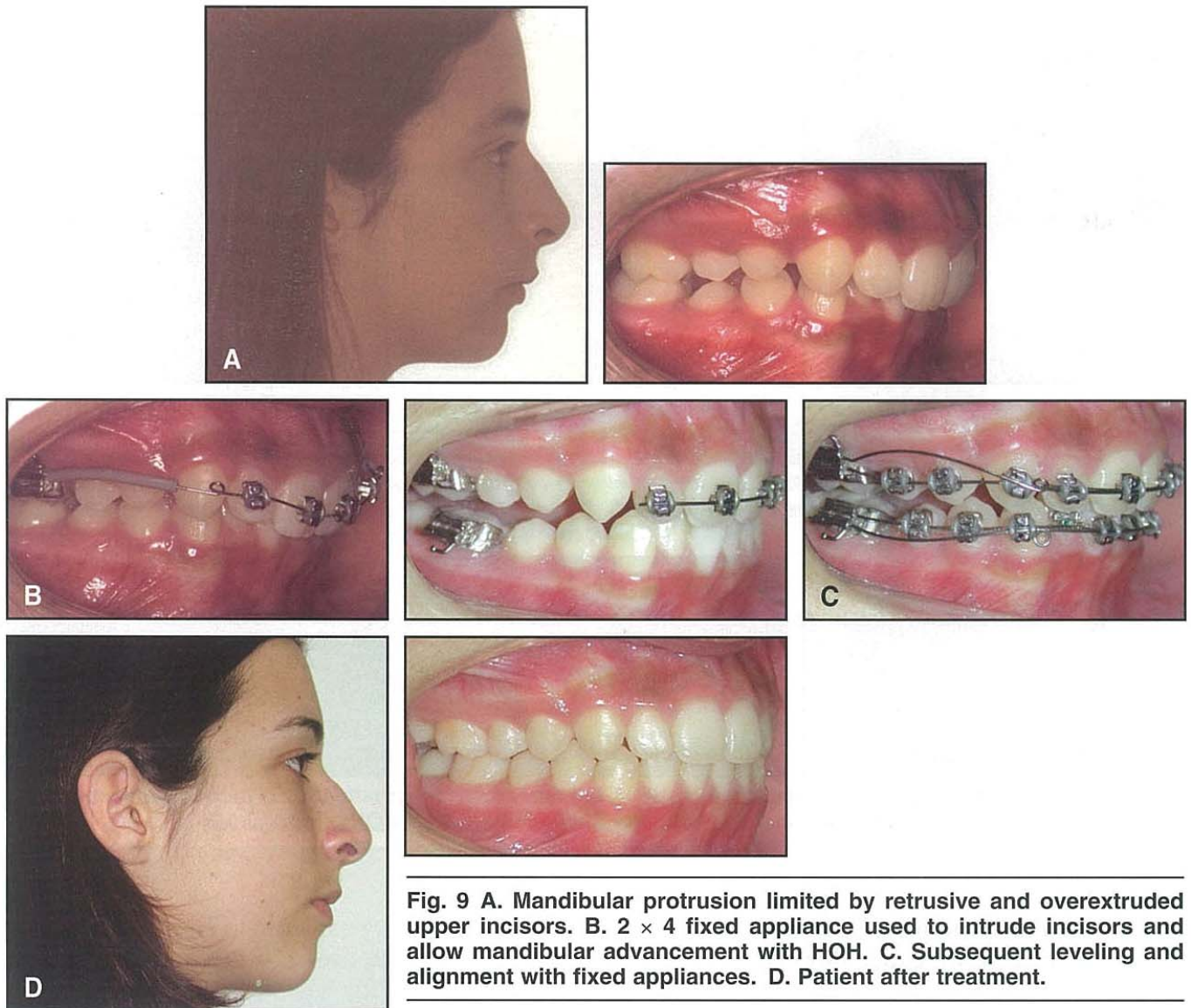


Fig. 9 A. Mandibular protrusion limited by retrusive and overextruded upper incisors. **B.** 2 × 4 fixed appliance used to intrude incisors and allow mandibular advancement with HOH. **C.** Subsequent leveling and alignment with fixed appliances. **D.** Patient after treatment.

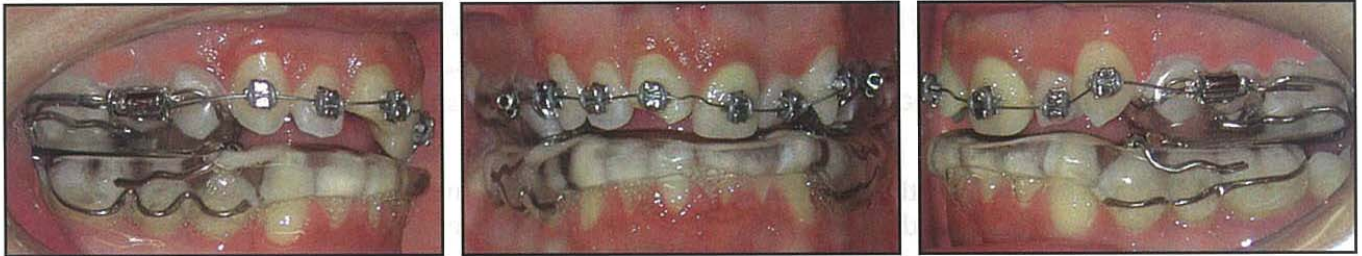

Fig. 10 HOH combined with fixed appliances.

REFERENCES

1. Herbst, E.: Meine Schiene für Prognathie (Okklusionsscharnier), in *Atlas und Grundriss der Zahnärztlichen Orthopädie*, J.F. Lehman Verlag, Munich, Germany, 1910, pp. 311-315.
2. Pancherz, H.: Treatment of Class II malocclusions by jumping the bite with the Herbst appliance: A cephalometric evaluation, *Am. J. Orthod.* 76:423-442, 1979.
3. Pancherz, H. and Hansen, K.: Mandibular anchorage in Herbst treatment, *Eur. J. Orthod.* 10:149-164, 1988.
4. Wolf, U.: Effekte der Herbst Appartur: Eine vergleichende studie zweier Konstruktionsformen, thesis, University of Gies-sen, Germany, 1994, pp. 1-123.
5. Hägg, U.; Tse, E.L.K.; Rabie, A.B.M.; and Robinson, W.: A comparison of splinted and banded Herbst appliances: Treatment changes and complications, *Aust. Orthod. J.* 18:76-81, 2002.
6. Vela-Hernandez, A.; Ponce de León, J.M.; Lasagabaster-Latorre, F.M.; and Rico-Lillo, I.: La "Bisagra Oclusal": Un nuevo aparato de avance mandibular, *Rev. Esp. Ortod.* 32:43-47, 2002.
7. Falck, F. and Frankel, R.: Clinical relevance of step-by-step mandibular advancement in the treatment of mandibular retrusion using the Frankel appliance, *Am. J. Orthod.* 96:333-341, 1989.
8. Rabie, A.B.M.; Wong, L.; and Hägg, U.: Correlation of replicating cells and osteogenesis in the glenoid fossa during step-wise advancement, *Am. J. Orthod.* 123:521-526, 2003.
9. Clark, W.J.: *Twin Block Functional Therapy*, Mosby, St. Louis, 1995.
10. Pancherz, H.: The effect of continuous bite jumping on the dentofacial complex: A follow-up study after Herbst appliance treatment of Class II malocclusions, *Eur. J. Orthod.* 3:49-60, 1981.
11. Pancherz, H.: The mechanism of Class II correction in Herbst appliance treatment: A cephalometric investigation, *Am. J. Orthod.* 82:104-113, 1982.
12. Pancherz, H. and Ruf, S.: The Herbst appliance: Research-based updated clinical possibilities, *World J. Orthod.* 1:17-31, 2000.